

International Association of Dental Traumatology guidelines for the management of traumatic dental injuries: 3. Injuries in the primary dentition

Barbro Malmgren^{1,*}, Jens O. Andreasen^{2,*}, Marie Therese Flores^{3,*}, Agneta Robertson^{4,*}, Anthony J. DiAngelis^{5,*}, Lars Andersson⁶, Giacomo Cavalleri⁷, Nestor Cohenca⁸, Peter Day⁹, Morris Lamar Hicks¹⁰, Olle Malmgren¹¹, Alex J. Moule¹², Juan Onetto¹³, Mitsuhiro Tsukiboshi¹⁴

¹Division of Pediatric Dentistry, Department of Dental Medicine, Karolinska Institutet, Huddinge, Sweden; ²Department of Oral and Maxillofacial Surgery, Center of Rare Oral Diseases, Copenhagen University Hospital, Rigshospitalet, Copenhagen, Denmark; ³Department of Pediatric Dentistry, Faculty of Dentistry, Universidad de Valparaiso, Valparaiso, Chile; ⁴Department of Pedodontics, Institute of Odontology, Gothenburg University, Gothenburg, Sweden; ⁵Department of Dentistry, Hennepin County Medical Center and University of Minnesota School of Dentistry, Minneapolis, MN, USA; ⁶Department of Surgical Sciences, Faculty of Dentistry, Health Sciences Center, Kuwait University, Kuwait City, Kuwait; ⁷Department of Dentistry, University of Verona, Verona, Italy; ⁸Department of Endodontics, University of Washington, Seattle, WA, USA; ⁹Pediatric Dentistry, Leeds Dental Institute and Bradford District Care Trust Salaried Dental Service, Leeds, UK; ¹⁰Department of Endodontics, University of Maryland School of Dentistry, Baltimore, MD, USA; ¹¹Orthodontic Clinic, Folk tandvården, Uppsala, Sweden; ¹²Private Practice, University of Queensland, Brisbane, QLD, Australia; ¹³Department of Pediatric Dentistry, Faculty of Dentistry, Universidad de Valparaiso, Valparaiso, Chile; ¹⁴Private Practice, Amagun, Aichi, Japan

Key words: tooth; trauma; primary; luxation; fracture; review

Correspondence to: Barbro Malmgren, DDS, PhD, DrMed, Karolinska Institutet, Department of Dental Medicine, Division of Pediatric Dentistry, POB 4064, SE-14104 Huddinge, Sweden

Tel.: +46 739851788

Fax: +46 8 7743395

e-mail: barbro.malmgren@ki.se

Accepted 26 March, 2012

*Members of the Task Group.

Abstract – Traumatic injuries to the primary dentition present special problems and the management is often different as compared with the permanent dentition. The International Association of Dental Traumatology (IADT) has developed a consensus statement after a review of the dental literature and group discussions. Experienced researchers and clinicians from various specialities were included in the task group. In cases where the data did not appear conclusive, recommendations were based on the consensus opinion or majority decision of the task group. Finally, the IADT board members were giving their opinion and approval. The primary goal of these guidelines is to delineate an approach for the immediate or urgent care for management of primary teeth injuries. The IADT cannot and does not guarantee favorable outcomes from strict adherence to the guidelines, but believe that their application can maximize the chances of a positive outcome.

Trauma to the oral region occurs frequently and comprises 5% of all injuries for which people seek treatment (1–3). In preschool children, head and facial non-oral injuries make up as much as 40% of all somatic injuries (1–3). In the age group 0–6 years, oral injuries are ranked as the second most common injury covering 18% of all somatic injuries (1–3). Of the oral injuries, dental injuries are the most frequent, followed by oral soft-tissue injuries. Luxation injuries affecting both multiple teeth and surrounding soft tissues are mainly reported in children 1–3 years of age and are typically as a result of falls (2, 4–11). Emergency situations therefore present a challenge to clinicians worldwide. It is now recognized that child injuries are a major threat to child health and that they are a neglected public health problem (12). A healthcare professional's decision on how to treat combined with parental consent and patient assent (13) is the preferred scenario encountered when facing pediatric emergencies (14).

Guidelines for the management of primary teeth injuries should assist dentists, other healthcare professionals, and parents or carers in decision making. They should be credible, readily understandable, and practical with the aim of delivering the best care possible in an efficient manner.

The International Association of Dental Traumatology (IADT) has developed an updated set of guidelines based on a review of the current dental literature utilizing EMBASE, MEDLINE, and PubMed searches from 1996 to 2011 as well as a search of the *Journal of Dental Traumatology* from 2000 to 2011. Search words included primary dentition, deciduous dentition, crown fracture, primary incisor fracture, tooth fractures, root fractures, tooth luxation, lateral luxation and primary teeth, intruded primary teeth, luxated primary teeth, tooth avulsion, and tooth/crown injuries. Additionally, some relevant articles prior to 1996, which have served as the basis for further research in the field of dental traumatology, as well as recent policy statements regarding holistic care and management of the injured child, were also included.

The IADT published its first set of guidelines in 2001 (15) and updated them in 2007 (16). As with the previous guidelines, the working group included experienced researchers and clinicians in pediatric dentistry and oral and maxillofacial surgery. This revision represents the best evidence from the available literature and expert professional judgement. In cases where the data did not appear conclusive, recommendations were based on the consensus opinion of the working group followed by review by the members of the IADT Board of Directors. It is understood that guidelines are to be applied with judgement of the specific clinical circumstances, clinicians' prudence, and patients' characteristics, including but not limited to compliance, finances and understanding of the immediate and long-term outcomes of treatment alternatives versus non-treatment. The IADT cannot and does not guarantee favorable outcomes from strict adherence to the Guidelines, but believe that their application can maximize the chances of a positive outcome. Guidelines undergo

periodic updates. These 2012 Guidelines in the journal *Dental Traumatology* appear in three parts.

Part I: Fractures and luxations of permanent teeth (*Dent Traumatol* 2012;28:issue 1)

Part II: Avulsion of permanent teeth (*Dent Traumatol* 2012;28:issue 2)

Part III: Injuries in the primary dentition (*Dent Traumatol* 2012;28:issue 3)

Guidelines offer recommendations for diagnosis and treatment of specific traumatic dental injuries (TDIs); however, they cannot provide comprehensive nor detailed information found in textbooks, scientific literature, and most recently the dental trauma guide (DTG).

The latter can be accessed on <http://www.dentaltraumaguide.org>. Additionally, the DTG is also available on the IADT web page (<http://www.iadt-dentaltrauma.org>) and provides a visual and animated documentation of treatment procedures as well as estimates of prognosis for the various TDIs.

Because the management of permanent and primary traumatized dentitions differs significantly, separate guidelines have been developed (Tables 1 and 2).

Special considerations for trauma to primary teeth

A young child is often difficult to examine and treat because of the lack of cooperation and because of fear. The situation is distressing for both the child and parents or carers (17).

Furthermore, there are varying conditions in different countries concerning economic and social aspects as well as treatment philosophies (7, 17, 18). However, child and family-centered pediatric practices and institutions should consider the best interests of children and prepare clinicians to ensure the fulfillment of children's rights when treatment decisions are made (19).

It is important to keep in mind that there is a close relationship between the apex of the root of the injured primary tooth and the underlying permanent tooth germ. Tooth malformation, impacted teeth, and eruption disturbances in the developing permanent dentition are some of the consequences that can occur following severe injuries to primary teeth and/or alveolar bone (5, 20–23). White or yellow-brown discoloration of crown and hypoplasia of permanent incisors are, however, the most common sequelae following intrusion and avulsion of primary teeth in children during the ages of 1–3 years (21–27). Because of these potential sequelae, treatment selections should be aimed at minimizing any additional risks of further damage to the permanent successors. It is therefore not recommended, for instance, to replant an avulsed primary incisor (16, 28, 29).

A child's maturity and ability to cope with the emergency situation, the time for shedding of the injured tooth, and the occlusion, are all important factors that influence treatment selection.

Repeated trauma episodes are frequent in children. It should be taken into consideration if planning root canal treatment in an injured primary tooth

Table 1. Treatment guidelines for fractures of teeth and alveolar bone







	Clinical findings	Radiographic findings	Treatment	Follow-up procedures for fractures of teeth and alveolar bone	Favorable and Unfavorable outcomes include some, but not necessarily all, of the following
				Favorable Outcome	Unfavorable Outcome
<p>Enamel fracture</p> 	<ul style="list-style-type: none"> Fracture involves enamel 	<ul style="list-style-type: none"> No radiographic abnormalities 	<ul style="list-style-type: none"> Smooth sharp edges 		
<p>Enamel dentin fracture</p> 	<ul style="list-style-type: none"> Fracture involves enamel and dentin; the pulp is not exposed 	<ul style="list-style-type: none"> No radiographic abnormalities. The relation between the fracture and the pulp chamber will be disclosed 	<p>If possible, seal completely the involved dentin with glass ionomer to prevent microleakage. In case of large lost tooth structure, the tooth can be restored with composite</p>	<p>3–4 weeks C</p>	
<p>Crown fracture with exposed pulp</p> 	<ul style="list-style-type: none"> Fracture involves enamel and dentin, and the pulp is exposed 	<ul style="list-style-type: none"> The stage of root development can be determined from one exposure 	<ul style="list-style-type: none"> If possible, preserve pulp vitality by partial pulpotomy. Calcium hydroxide is a suitable material for such procedures. A well-condensed layer of pure calcium hydroxide paste can be applied over the pulp, covered with a lining such as reinforced glass ionomer. Restore the tooth with composite The treatment is depending on the child's maturity and ability to cope. Extraction is usually the alternative option 	<p>1 week C 6–8 weeks C+R 1 year C+R</p>	<ul style="list-style-type: none"> Continuing root development in immature teeth and a hard tissue barrier Signs of apical periodontitis; no continuing root development in immature teeth Extraction or root canal treatment
<p>Crown–root fracture</p>					

Table 1. Continued

	Clinical findings	Radiographic findings	Treatment	Follow-up procedures for fractures of teeth and alveolar bone	Favorable and Unfavorable outcomes include some, but not necessarily all, of the following
					Favorable Outcome Unfavorable Outcome
	<ul style="list-style-type: none"> Fracture involves enamel, dentin, and root structure; the pulp may or may not be exposed Additional findings may include loose, but still attached, fragments of the tooth There is minimal to moderate tooth displacement 	<ul style="list-style-type: none"> In laterally positioned fractures, the extent in relation to the gingival margin can be seen One exposure is necessary to disclose multiple fragments 	<p>Depending on the clinical findings, two treatment scenarios may be considered:</p> <ul style="list-style-type: none"> Fragment removal only if the fracture involves only a small part of the root and the stable fragment is large enough to allow coronal restoration Extraction in all other instances 	<p>In cases of fragment, removal only:</p> <p>1 week C 6–8 weeks C+R 1 year C(*)</p>	<ul style="list-style-type: none"> Asymptomatic; continuing root development in immature teeth Symptomatic; signs of apical periodontitis; no continuing root development in immature teeth
<p>Root fracture</p> 	<ul style="list-style-type: none"> The coronal fragment may be mobile and may be displaced 	<ul style="list-style-type: none"> The fracture is usually located mid-root or in the apical third 	<ul style="list-style-type: none"> If the coronal fragment is not displaced, no treatment is required If the coronal fragment is displaced, repositioning and splinting might be considered Otherwise extract only that fragment. The apical fragment should be left to be resorbed 	<ul style="list-style-type: none"> No displacement: 1 week C, 6–8 weeks C, 1 year C+R and C(*) each subsequent year until exfoliation Extraction 1 year C+R and C(*) each subsequent year until exfoliation 	<ul style="list-style-type: none"> Signs of repair between fractured segments Continuous resorption of the left apical fragment None
<p>Alveolar fracture</p> 	<ul style="list-style-type: none"> The fracture involves the alveolar bone and may extend to adjacent bone Segment mobility and dislocation are common findings Occlusal interference is often noted 	<ul style="list-style-type: none"> The horizontal fracture line to the apices of the primary teeth and their permanent successors will be disclosed A lateral radiograph may also give information about the relation between the two dentitions and if the segment is displaced in labial direction 	<ul style="list-style-type: none"> Reposition any displaced segment and then splint General anesthesia is often indicated Stabilize the segment for 4 weeks Monitor teeth in fracture line 	<p>1 week C 3–4 weeks S+C +R 6–8 weeks C +R 1 year C+R and C(*) each subsequent year until exfoliation</p>	<ul style="list-style-type: none"> Normal occlusion No signs of apical periodontitis No signs of disturbances in the permanent successors Signs of apical periodontitis or external inflammatory root resorption of primary teeth Signs of disturbances in the permanent successors require follow up until full eruption

C, Clinical examination; R, Radiographic examination; S, Splint removal; (C*), Clinical and radiographic monitoring until eruption of the permanent successor.

because trauma recurrence will shorten the survival time for the primary tooth (30).

There is no consensus in the literature about best treatment for the traumatized primary dentition. Furthermore, children with dental injuries are not always brought in for treatment immediately, which may be due to lack of access to dental care (31, 32). While some reports advocate routine tooth extraction, others stress the importance of a more conservative approach by saving primary teeth whenever possible (29, 33). Traumatic pulp exposures of primary incisors are rare but can be treated with partial pulpotomy (34). Pulpotomy with zinc oxide eugenol or calcium hydroxide/iodoform paste is recommended in some countries (30,35,36). However, if full cooperation of the child can not be achieved, extraction is usually the alternative option.

It has been demonstrated that most luxation injuries heal spontaneously (37, 38), avoiding the traumatic experience of a tooth extraction. The clinician's skills and experience with pediatric patients is of utmost importance for managing the patient's and the parents' or carers' behavior in the emergency situation (17). After an accurate diagnosis and explanation of various treatment options to the parents or carers, the clinician and parents or carers must decide the treatment planning for the child's own benefit.

Guidelines for the clinician

These Guidelines contain recommendations for diagnosis and treatment of traumatic injuries in the primary dentition, for caries-free, healthy primary teeth, using proper examination procedures.

Clinical examination

Information about the examination of traumatic injuries in the primary dentition can be found in a number of current textbooks (4, 39). The possibility of child abuse should be considered when assessing children under the age of 5 years who present with intra-oral trauma affecting the lips, gums, tongue, palate, and severe tooth injuries (40–46).

Radiographic examination

A detailed radiographic examination is essential to establish the extent of the injury to the supporting tissues, the stage of root development, and the relation to the permanent successors. Depending on the child's ability to cope with the procedure and the type of injury suspected, the clinician should decide which radiograph is required for confirming diagnosis. Always consider minimizing the risk of radiation to the child. Several angles are recommended. Select the appropriate radiographic examination:

- 1 90° horizontal angle with central beam through the tooth in question (size 2 film, horizontal view)
- 2 Occlusal view (size 2 film, horizontal view)

- 3 Extra-oral lateral view of the tooth in question may reveal the relationship between the apex of the displaced tooth and the permanent tooth germ as well as the direction of dislocation (size 2 film, vertical view), but is seldom indicated as it rarely adds extra information.

Splinting

Splinting is used only for alveolar bone fractures and possibly for intra-alveolar root fractures.

Use of antibiotics

There is no evidence for the use of systemic antibiotics in the management of luxation injuries in the primary dentition. Antibiotic use remains at the discretion of the clinician as TDIs are often accompanied by soft tissue and other associated injuries that may require significant surgical intervention. In addition, the child's medical status may warrant antibiotic coverage. Whenever possible, contact the pediatrician who may give recommendations for a specific medical condition.

Sensibility and percussion tests

Sensibility and percussion tests are not reliable in primary teeth because of the inconsistent results.

Crown discoloration

Although these Guidelines recommendations focus on the management of acute dental injuries, crown discoloration may be considered as it is a frequently asked question by the parents or carers, mainly for esthetic reasons. Discoloration is a common complication after luxation injuries (47–50). Such discoloration may fade, and the tooth may regain its original shade (8, 47, 50, 51). Teeth with persisting dark discoloration may remain asymptomatic clinically and radiographically or they may develop apical periodontitis (52, 53). There is an association between crown discoloration and pulp necrosis in traumatized primary teeth (48, 54). Unless associated infection exists, root canal treatment is not indicated (55).

Pulp canal obliteration

Pulp canal obliteration is common sequela to luxation injuries. It has been found to occur in 35–50% (48, 50, 53) and indicates ongoing pulp vitality (48, 56). A yellowish hue can be noted.

Parents' instructions

Good healing following an injury to the teeth and oral tissues depends, in part, on good oral hygiene. To optimize healing, parents and carers should be advised regarding care of the injured tooth/teeth and the prevention of further injury by supervising potentially

Table 2. Treatment guidelines for luxation injuries




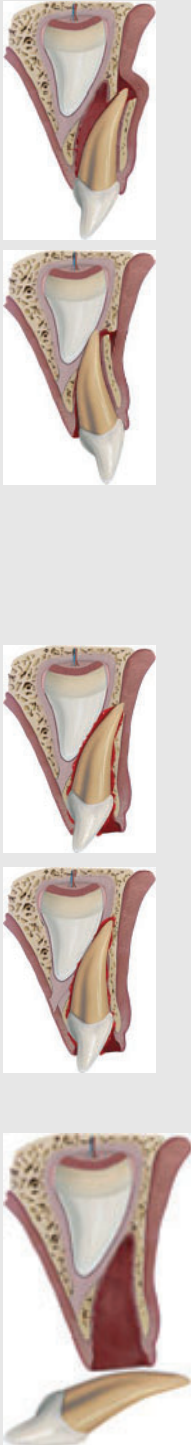
	Clinical findings	Radiographic findings	Treatments	Follow up	Favorable Outcome	Unfavorable Outcome
<p>Concussion</p> 	<ul style="list-style-type: none"> The tooth is tender to touch. It has normal mobility and no sulcular bleeding 	<p>No radiographic abnormalities. Normal periodontal space</p>	<ul style="list-style-type: none"> No treatment is needed. Observation 	<p>1 week C 6–8 weeks C</p>	<ul style="list-style-type: none"> Continuing root development in immature teeth 	<ul style="list-style-type: none"> No continuing root development in immature teeth Dark discoloration of crown. No treatment is needed unless apical periodontitis develops
<p>Subluxation</p> 	<ul style="list-style-type: none"> The tooth has increased mobility but has not been displaced Bleeding from gingival crevice may be noted 	<p>Radiographic abnormalities are usually not found. Normal periodontal space. An occlusal exposure is recommended to screen for possible signs of displacement or the presence of a root fracture. The radiograph can furthermore be used as a reference point in case of future complications</p>	<ul style="list-style-type: none"> No treatment is needed. Observation. Brushing with a soft brush and use of alcohol-free 0.12% chlorhexidine topically on the affected area with cotton swabs twice a day for 1 week 	<p>1 week C 6–8 weeks C Crown discoloration might occur. No treatment is needed unless a fistula develops. Dark discolored teeth should be followed carefully to detect sign of infection as soon as possible</p>	<ul style="list-style-type: none"> Continuing root development in immature teeth Transient red/gray discoloration. A yellow discoloration indicates pulp obliteration and has a good prognosis 	<ul style="list-style-type: none"> No continuing root development in immature teeth Dark discoloration of crown. No treatment is needed unless apical periodontitis develops
<p>Extrusive luxation</p> 	<ul style="list-style-type: none"> Partial displacement of the tooth out of its socket The tooth appears elongated and can be excessively mobile 	<p>Increased periodontal ligament space apically</p>	<ul style="list-style-type: none"> Treatment decisions are based on the degree of displacement, mobility, root formation, and the ability of the child to cope with the emergency situation For minor extrusion (<3 mm) in an immature developing tooth, careful repositioning or leaving the tooth for spontaneous alignment can be treatment options. Extraction is the treatment of choice for severe extrusion in a fully formed primary tooth 	<p>1 week C 6–8 weeks C +R 6 months C+R 1 year C+R Discoloration might occur. Dark discolored teeth should be followed carefully to detect sign of infection as soon as possible</p>	<ul style="list-style-type: none"> Continuing root development in immature teeth Transient red/gray discoloration. A yellow discoloration indicates pulp obliteration and has a good prognosis 	<ul style="list-style-type: none"> No continuing root development in immature teeth Dark discoloration of crown. No treatment is needed unless apical periodontitis develops

Table 2. Continued

	Clinical findings	Radiographic findings	Treatments	Follow up	Favorable and Unfavorable outcomes include some, but not necessarily all, of the following Favorable Outcome	Unfavorable Outcome
<p>Lateral luxation</p> 	<ul style="list-style-type: none"> The tooth is displaced, usually in a palatal/lingual, or labial direction It will be immobile 	<p>Increased periodontal ligament space apically is best seen on the occlusal exposure. And an occlusal exposure can sometimes also show the position of the displaced tooth and its relation to the permanent successor</p>	<ul style="list-style-type: none"> If there is no occlusal interference, as is often the case in anterior open bite, the tooth is allowed to reposition spontaneously In case of minor occlusal interference, slight grinding is indicated When there is more severe occlusal interference, the tooth can be gently repositioned by combined labial and palatal pressure after the use of local anesthesia In severe displacement, when the crown is dislocated in a labial direction, extraction is the treatment of choice 	<p>1 week C 2–3 weeks C 6–8 weeks C +R 1 year C+R</p>	<ul style="list-style-type: none"> Asymptomatic Clinical and radiographic signs of normal or healed periodontium Transient discoloration might occur 	<ul style="list-style-type: none"> No continuing root development in immature teeth Dark discoloration of crown No treatment is needed unless apical periodontitis develops
	<ul style="list-style-type: none"> The tooth is usually displaced through the labial bone plate, or can be impinging upon the succedaneous tooth bud 	<p>When the apex is displaced toward or through the labial bone plate, the apical tip can be visualized and the tooth appears shorter than its contra lateral</p> <p>When the apex is displaced toward the permanent tooth germ, the apical tip cannot be visualized and the tooth appears elongated</p>	<p>If the apex is displaced toward or through the labial bone plate, the tooth is left for spontaneous repositioning</p> <p>If the apex is displaced into the developing tooth germ, extract</p>	<p>1 week C 3–4 weeks C + R 6–8 weeks C 6 months C+R • 1 year C+R and (C*)</p>	<ul style="list-style-type: none"> Tooth in place or erupting No or transient discoloration 	<ul style="list-style-type: none"> Tooth locked in place Persistent discoloration Radiographic signs of apical periodontitis Damage to the permanent successor
	<p>The tooth is completely out of the socket</p>	<p>A radiographic examination is essential to ensure that the missing tooth is not intruded</p>	<p>It is not recommended to replant avulsed primary teeth</p>	<p>1 week C 6 months C + R 1 year C + R and (C*)</p>		<p>Damage to the permanent successor</p>

C, Clinical examination; R, Radiographic examination; (C*), Clinical and radiographic monitoring until eruption of the permanent successor.

hazardous activities. Brushing with a soft brush and use of alcohol-free 0.1% chlorhexidine gluconate topically on the affected area with cotton swabs twice a day for 1 week are recommended to prevent accumulation of plaque and debris. A soft diet for 10 days and restriction in the use of an intra-oral pacifier are also recommended.

Parents or carers should be further advised about possible complications that may occur, like swelling, increased mobility, or sinus tracts. Children may not complain about pain; however, infection may be present, and parents or carers should watch for signs such as swelling of the gums; if present they should bring the children in for treatment.

Documentation that the parents and carers have been informed about possible complications in the development of the permanent teeth, especially following intrusion, avulsion, and alveolar fracture injuries, is very important.

Acknowledgments

IADT is grateful to the team of Dental Trauma guide www.dentaltraumaguide.org for kindly providing pictures to the article.

References

- Glendor U, Andersson L. Public health aspects of oral diseases and disorders; dental trauma. In: Pine C, Harris R, editors. *Community oral health*. London: Quintessence 2007; p.203–14.
- Glendor U, Halling A, Andersson L, Eilert-Petersson E. Incidence of traumatic tooth injuries in children and adolescents in the county of Vastmanland, Sweden. *Swed Dent J* 1996;20:15–28.
- Petersson EE, Andersson L, Sorensen S. Traumatic oral vs non-oral injuries. *Swed Dent J* 1997;21:55–68.
- Flores MT, Holan G, Borum M, Andresen JO. Injuries to the primary dentition. In: *Andreasen JO, Andreasen FM, Andersson L, editors. Textbook and color atlas of traumatic injuries to the teeth, 4th edn. Oxford, England: Blackwell Munksgaard; 2007. p. 516–41.*
- Andreasen JO, Ravn JJ. Epidemiology of traumatic dental injuries to primary and permanent teeth in a Danish population sample. *Int J Oral Surg* 1972;1:235–9.
- Cunha RF, Pugliesi DM, de Mello Vieira AE. Oral trauma in Brazilian patients aged 0–3 years. *Dent Traumatol* 2001;17:210–2.
- Borum MK, Andreasen JO. Therapeutic and economic implications of traumatic dental injuries in Denmark: an estimate based on 7549 patients treated at a major trauma centre. *Int J Paediatr Dent* 2001;11:249–58.
- Fried I, Erickson P, Schwartz S, Keenan K. Subluxation injuries of maxillary primary anterior teeth: epidemiology and prognosis of 207 traumatized teeth. *Pediatr Dent* 1996;18:145–51.
- Llarena del Rosario ME, Acosta Alfaro VM, Garcia-Godoy F. Traumatic injuries to primary teeth in Mexico City children. *Endod Dent Traumatol* 1992;8:213–4.
- Bastone EB, Freer TJ, McNamara JR. Epidemiology of dental trauma: a review of the literature. *Aust Dent J* 2000;45:2–9.
- McTigue DJ. Diagnosis and management of dental injuries in children. *Pediatr Clin North Am* 2000;47:1067–84.
- World Health Organization. World report on child injury prevention. World Health Organization; 2008. Chapter 7. p. 145–55. http://whqlibdoc.who.int/publications/2008/9789241563574_eng.pdf (accessed 6 November 2011).
- Harding AM. Pharmacologic considerations in pediatric dentistry. *Dent Clin North Am* 1994;38:733–53.
- American Academy of Pediatrics. Policy statement- Consent for emergency medical services for children and adolescents. *Pediatrics* 2011;128:427–33.
- Flores MT, Andreasen JO, Bakland LK, Feiglin B, Gutmann JL, Oikarinen K et al. Guidelines for the evaluation and management of traumatic dental injuries. *Dent Traumatol* 2001;17:1–4.
- Flores MT, Malmgren B, Andersson L, Andreasen JO, Bakland LK, Barnett F et al. Guidelines for the management of traumatic dental injuries. III. Primary teeth. *Dent Traumatol* 2007;23:196–202.
- Needleman HL. The art and science of managing traumatic injuries to primary teeth. *Dent Traumatol* 2011;27:295–9.
- Vlok JL, Worthington EM, Hindson JA, Davidson LE, Thomson WM, Drummond BK. Young people's perceptions of photographs of dental trauma. *Dent Traumatol* 2011;27:109–12.
- American Academy of Pediatrics. Policy statement-health equity and children's rights. *Pediatrics* 2010;125:838–49.
- Andreasen JO, Sundstrom B, Ravn JJ. The effect of traumatic injuries to primary teeth on their permanent successors. I. A clinical and histologic study of 117 injured permanent teeth. *Scand J Dent Res* 1971;79:219–83.
- Diab M, elBadrawy HE. Intrusion injuries of primary incisors. Part III: effects on the permanent successors. *Quintessence Int* 2000;31:377–84.
- Ravn JJ. Developmental disturbances in permanent teeth after intrusion of their primary predecessors. *Scand J Dent Res* 1976;84:137–41.
- Holan G, Ram D. Sequelae and prognosis of intruded primary incisors: a retrospective study. *Pediatr Dent* 1999;21:242–7.
- de Amorim Lde F, da Costa LR, Estrela C. Retrospective study of traumatic dental injuries in primary teeth in a Brazilian specialized pediatric practice. *Dent Traumatol* 2011; 27:368–73.
- Da Silva Assuncao LR, Ferelle A, Iwakura ML, Cunha RF. Effects on permanent teeth after luxation injuries to the primary predecessors: a study in children assisted at an emergency service. *Dent Traumatol* 2009;25:165–70.
- do Espirito Santo Jacomo DR, Campos V. Prevalence of sequelae in the permanent anterior teeth after trauma in their predecessors: a longitudinal study of 8 years. *Dent Traumatol* 2009;25:300–4.
- Altun C, Cehreli ZC, Guven G, Acikel C. Traumatic intrusion of primary teeth and its effects on the permanent successors: a clinical follow-up study. *Oral Surg Oral Med Oral Pathol Oral Radiol Endod* 2009;107:493–8.
- Christophersen P, Freund M, Harild L. Avulsion of primary teeth and sequelae on the permanent successors. *Dent Traumatol* 2005;21:320–3.
- Flores MT. Traumatic injuries in the primary dentition. *Dent Traumatol* 2002;18:287–98.
- Rocha MJ, Cardoso M. Survival analysis of endodontically treated traumatized primary teeth. *Dent Traumatol* 2007;23:340–7.
- Avsar A, Topaloglu B. Traumatic tooth injuries to primary teeth of children aged 0–3 years. *Dent Traumatol* 2009;25: 323–7.
- Lam R, Abbott P, Lloyd C, Kruger E, Tennant M. Dental trauma in an Australian rural centre. *Dent Traumatol* 2008;24:663–70.
- Cunha RF, Pugliesi DM, Percinoto C. Treatment of traumatized primary teeth: a conservative approach. *Dent Traumatol* 2007;23:360–3.

34. Kupietzky A, Holan G. Treatment of crown fractures with pulp exposure in primary incisors. *Pediatr Dent* 2003;25:241–7.
35. Trairatvorakul C, Chunlasikawaiwan S. Success of pulpectomy with zinc oxide-eugenol vs calcium hydroxide/iodoform paste in primary molars: a clinical study. *Pediatr Dent* 2008;30:303–8.
36. Rocha MJ, Cardoso M. Federal University of Santa Catarina endodontic treatment of traumatized primary teeth - part 2. *Dent Traumatol* 2004;20:314–26.
37. Colak I, Markovic D, Petrovic B, Peric T, Milenkovic A. A retrospective study of intrusive injuries in primary dentition. *Dent Traumatol* 2009;25:605–10.
38. Spinis E, Melis A, Savasta A. Therapeutic approach to intrusive luxation injuries in primary dentition. A clinical follow-up study. *Eur J Paediatr Dent* 2006;7:179–86.
39. Andreasen JO, Bakland LK, Flores MT, Andreasen FM, Andersson L. Traumatic dental injuries, a manual. 3rd edn. Chichester, West Sussex: Wiley-Blackwell; 2011. p. 54–7
40. Kellogg N. Oral and dental aspects of child abuse and neglect. *Pediatrics* 2005;116:1565–8.
41. Becker DB, Needleman HL, Kotelchuck M. Child abuse and dentistry: orofacial trauma and its recognition by dentists. *J Am Dent Assoc* 1978;97:24–8.
42. Tate RJ. Facial injuries associated with the battered child syndrome. *Br J Oral Surg* 1971;9:41–5.
43. da Fonseca MA, Feigal RJ, ten Bense RW. Dental aspects of 1248 cases of child maltreatment on file at a major county hospital. *Pediatr Dent* 1992;14:152–7.
44. Jessee SA. Physical manifestations of child abuse to the head, face and mouth: a hospital survey. *ASDC J Dent Child* 1995;62:245–9.
45. Naidoo S. A profile of the oro-facial injuries in child physical abuse at a children's hospital. *Child Abuse Negl* 2000;24:521–34.
46. Cairns AM, Mok JY, Welbury RR. Injuries to the head, face, mouth and neck in physically abused children in a community setting. *Int J Paediatr Dent* 2005;15:310–8.
47. Auslander WP. Discoloration, a traumatic sequela. *N Y State Dent J* 1967;33:534–8.
48. Schroder U, Wennberg E, Granath LE, Moller H. Traumatized primary incisors - follow-up program based on frequency of periapical osteitis related to tooth color. *Swed Dent J* 1977;1:95–8.
49. Reed AJ 3rd, Sayegh FS. The dark primary incisor. *Dent Surv* 1978;54:16–9.
50. Borum MK, Andreasen JO. Sequelae of trauma to primary maxillary incisors. I. Complications in the primary dentition. *Endod Dent Traumatol* 1998;14:31–44.
51. Jacobsen I, Sangnes G. Traumatized primary anterior teeth. Prognosis related to calcific reactions in the pulp cavity. *Acta Odontol Scand* 1978;36:199–204.
52. Holan G, Fuks AB. The diagnostic value of coronal dark-gray discoloration in primary teeth following traumatic injuries. *Pediatr Dent* 1996;18:224–7.
53. Holan G. Development of clinical and radiographic signs associated with dark discolored primary incisors following traumatic injuries: a prospective controlled study. *Dent Traumatol* 2004;20:276–87.
54. Cardoso M, de Carvalho Rocha MJ. Association of crown discoloration and pulp status in traumatized primary teeth. *Dent Traumatol* 2010;26:413–6.
55. Holan G. Long-term effect of different treatment modalities for traumatized primary incisors presenting dark coronal discoloration with no other signs of injury. *Dent Traumatol* 2006;22:14–7.
56. Robertson A, Lundgren T, Andreasen JO, Dietz W, Hoyer I, Noren JG. Pulp calcifications in traumatized primary incisors. A morphological and inductive analysis study. *Eur J Oral Sci* 1997;105:196–206.